

Syrian hamsters as a small animal model for SARS-CoV-2 infection and countermeasure development

At the end of 2019, a novel coronavirus (severe acute respiratory syndrome coronavirus 2; SARS-CoV-2) was detected in Wuhan, China. Since then, SARS-CoV-2 has spread rapidly around the world, infecting millions of people resulting in severe consequences for global human health and the economy. Consequently, effective vaccines and therapeutics for SARS-CoV-2-induced disease (COVID-19) are urgently needed.

The authors of this publication assessed the replicative ability and pathogenesis of SARS-CoV-2 isolates in Syrian hamsters. Results showed that SARS-CoV-2 isolate can efficiently replicate and cause severe pathological lesions in the lungs of Syrian hamsters following intranasal infection. Interestingly, these lung lesions were similar to the commonly reported imaging features of COVID-19 patients with pneumonia. Other findings included that SARS-CoV-2-infected hamsters mounted neutralizing antibody responses and were protected against a re-challenge by the SARS-CoV-2 virus. Moreover, passive transfer of convalescent serum to naïve hamsters inhibited virus replication in lung tissue.

Preclinical computed tomography (CT) imaging elucidated severe lung injury that shared characteristics observed in human lungs infected with SARS-CoV-2. Some of these characteristics included severe bilateral peripherally distributed multi-lobular ground glass opacities and regions of lung consolidation. In summary, these findings demonstrate that microCT imaging along with the Syrian hamster model are both useful tools for understanding SARS-CoV-2 pathogenesis and testing vaccines and antiviral drugs against this virus.

Publication authors


Masaki Imai,
Yoshihiro Kawaoka and Colleagues

Division of Virology, Department of Microbiology and Immunology, Institute of Medical Science, University of Tokyo, Tokyo, Japan Influenza Research Institute, Department of Pathobiological Sciences, School of Veterinary Medicine, University of Wisconsin-Madison, Madison, WI, USA

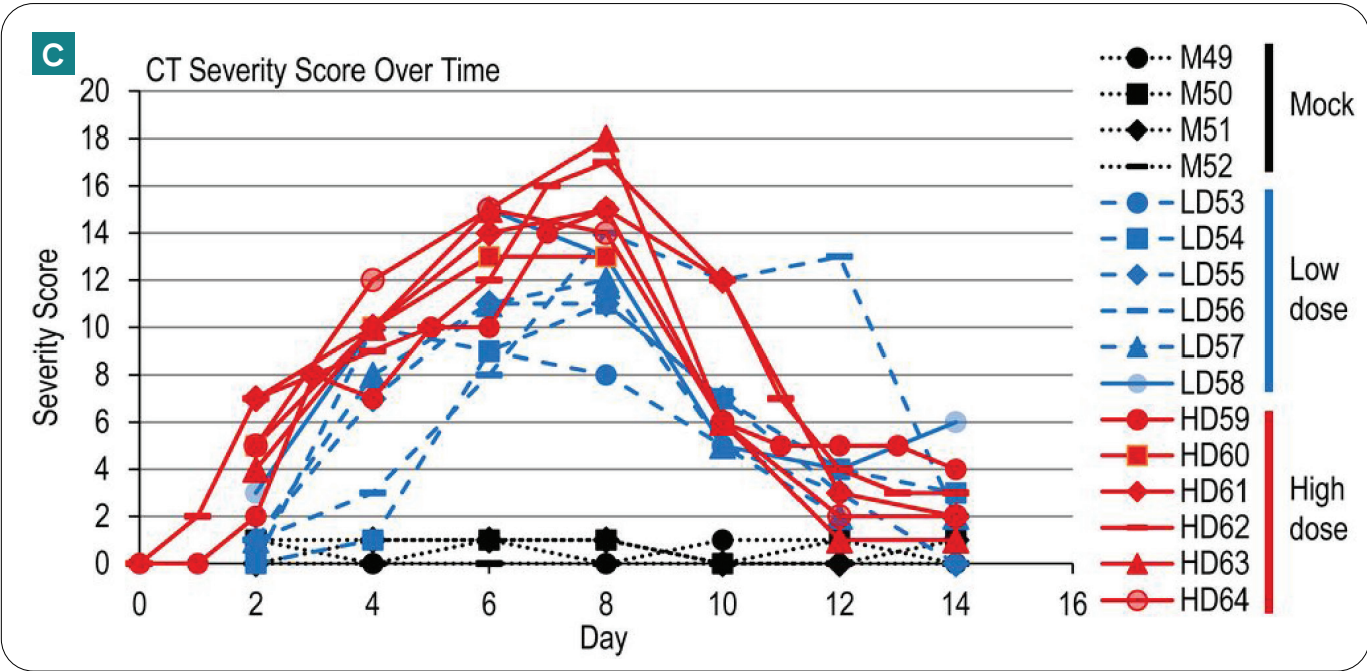
Source:
PNAS July 14, 2020 117 (28) 16587-16595

Publication highlights:


Non-invasive CT imaging using a Quantum microCT system successfully quantified lung abnormalities over a 14 day period after infection with SARS-CoV-2 in Syrian hamsters. Lung abnormalities were first detected two days postinfection, and the most severe changes were observed eight days postinfection in virus-infected animals. These results highlight the utility of Quantum microCT technology for preclinical infectious disease lung research.



A) A 3D CT image rendering of the lungs of an uninfected Syrian hamster. The blue pseudo-coloring indicates the trachea and bronchi of the lungs. B) A 3D CT image rendering of the lungs of an infected Syrian hamster at day seven postinfection. The blue pseudo-coloring indicates the trachea and bronchi of the lungs while the red highlights the presence of pneumothorax.



C) Graph shows the severity of lung abnormalities in mock-infected control and infected Syrian hamsters (low and high dose) with SARS-CoV-2 based on CT images over a 14 day period. CT abnormalities were first detected two days postinfection with the most severe changes peaked at 6-8 days post-infection and the recovery period beginning 10 days postinfection. Higher CT severity scores correlated with an increase in the severity of lung abnormalities. As such, high CT severity scores were observed in high dose infected animals compared to low dose and mock-infected control animals.



revvity