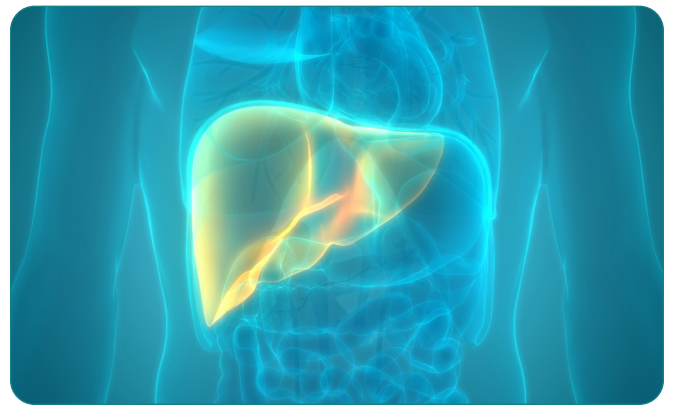


A novel non-invasive *in vivo* diagnostic tool for the assessment of NASH

Introduction

Non-alcoholic fatty liver disease (NAFLD) describes a progressive pathology that affects the liver. Fat accumulation causes fatty liver (NAFL) or steatosis to develop, which leads to lipotoxicity and in turn induces liver inflammation and apoptosis, resulting in non-alcoholic steatohepatitis (NASH). NASH can progress to fibrosis and then cirrhosis, which in some cases will lead to hepatocellular carcinoma (HCC) (Fig. 1). NASH may be partially caused by chronic excessive calorie intake and a sedentary lifestyle and is distinct from other fatty liver diseases caused by alcohol abuse or medication side effects.

Other risk factors associated with NASH include obesity, type 2 diabetes, dyslipidemia, hypertension, and metabolic syndrome. Worldwide prevalence of NAFLD is 25.2% and ranges between 1.5 and 6.5% for NASH, with wide geographical variation across the globe (US: 34% NAFLD, 12% NASH) [1]. NASH is expected to be the leading cause of liver transplantation in the near future. The gold standard for NASH diagnosis is an invasive liver biopsy. Currently, non-invasive diagnostic methods such as blood biomarkers or imaging-based techniques lack sufficient accuracy; thus, there is an urgent need for new NASH diagnostic tools.



Our challenge



“At Galapagos, we are looking for innovative strategies to aid in the development of NASH diagnostic tools. In order to develop new therapies, it’s

necessary to understand the different stages of this multiparametric liver disease, particularly that of fibrosis. In order to easily and quickly diagnose NASH, we needed to establish a novel non-invasive preclinical *in vivo* imaging protocol to visualize and quantify disease progression.”

Dr. Ludovic Waeckel

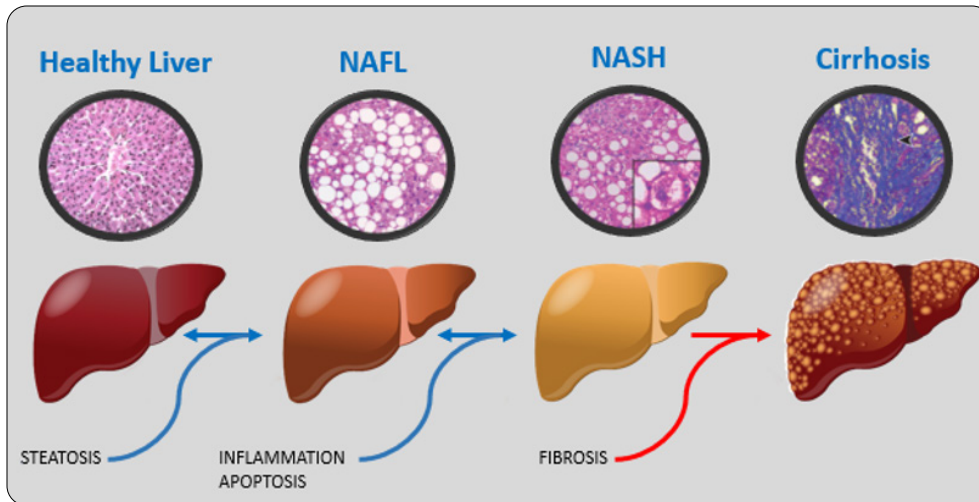


Figure 1: NAFLD disease progression. Representative hematoxylin eosin staining from histological analysis (circled). Reversible steps are displayed with blue arrows and irreversible step with a red arrow.

The challenge

NASH is a multiparametric disease that may include liver steatosis, inflammation, fibrosis, and hepatocellular death. Histology is currently the gold standard for NASH diagnosis and requires an invasive liver biopsy followed by hematoxylin and eosin (H&E) staining. A NAFLD Activity Score (NAS) composed of three major criteria is assessed from each biopsy.

The first assessment is of liver steatosis to provide the percentage of fat droplet accumulation in hepatocyte liver cells. The second is of lobular inflammation, which is defined by acute and chronic inflammatory cell infiltrate. The third criteria assesses hepatocellular injury and usually occurs in the form of ballooning, but it can also be present as apoptotic (acidophilic) bodies and lytic necrosis [2]. Due to the number of disease features that must be assessed, a single diagnostic method cannot be used. The challenge was to find a combination of techniques that could provide a non-invasive diagnosis of NASH.

NASH: A non-invasive strategy

In order to study NASH diagnostic parameters non-invasively, a combination of fluorescence and chemiluminescence imaging using the IVIS[®] Lumina Series III optical system, and computed tomography with the Quantum GX2 microCT system, was used in a well-established choline-deficient, L-amino acid-defined, high-fat diet (CDAHFD) preclinical NASH mouse model.

Liver steatosis assessment was performed using CT without a contrast agent as fat accumulation causes a reduction in liver density and is therefore easily identifiable with CT imaging. Inflammation was evaluated using Lucigenin, a chemiluminescent probe which identifies reactive oxygen species (ROS) production, especially the anion superoxide O_2^- , which is produced during exacerbated mitochondrial fatty acid β -oxidation (lipotoxicity) [3] and leukocyte recruitment [4].

A second inflammation marker was used to monitor leukocyte recruitment and activation by imaging cathepsin B protease activity using the smart fluorescent probe, IVISense[™] Cat B 680 FAST [5]. IVISense Cat B 680 FAST is an activatable agent (optically silent upon injection) that produces fluorescent signal after cleavage by cathepsin B, which is produced by inflammatory cells such as Kupffer liver cells and activated macrophages. Both oxidative stress and cathepsin B overexpression lead to hepatocellular apoptosis [6]. Apoptosis is then measured using a second fluorescent probe (IVISense Annexin-V 750) containing an Annexin A5 moiety which binds to phosphatidylserine flipping on the outer leaflet of the plasma membrane during the early stages of apoptosis.

Using this unique multimodal *in vivo* imaging approach, liver steatosis, inflammation (oxidative stress, leukocyte activation/recruitment), as well as hepatocellular injury (apoptosis) can be assessed in the same animal longitudinally and in turn could be used to diagnose NASH non-invasively.

The outcome

Mice were fed a high fat diet for either one (W1) or three (W3) weeks to induce NAFL or NASH, respectively. The control group were fed regular chow throughout the study. CT and optical imaging for the disease (CDAHFD) and control groups are shown in Fig 2A. MicroCT imaging revealed a statistically significant reduction ($p < 0.001$) in liver density for the high-fat diet (CDAHFD) group compared to the control group.

This result suggests that liver steatosis is present at both W1 and W3 and can be assessed and quantified using non-invasive CT imaging. Using fluorescence imaging biomarkers, inflammation and apoptosis were not statistically different ($p > 0.05$) in the diseased versus control group at W1, but statistically significant differences were observed at W3 ($p < 0.01$ and $p < 0.001$). The latter may be due to oxidative stress. Leucocyte activation, recruitment, and subsequent apoptosis occurred between W1 and W3 as per histological analysis [7].

Optical and microCT Imaging approach

“The highly sensitive IVIS™ Lumina III optical imaging system combined with Revvity’s novel reagents and application support was used to perform chemiluminescence and fluorescence imaging to assess the apoptotic and inflammatory components of NASH progression. With the addition of the fast, low dose *in vivo* imaging capabilities of the Quantum GX2 microCT, we could also easily, quickly and accurately quantify both liver steatosis and fibrosis.”

Dr. Ludovic Waeckel

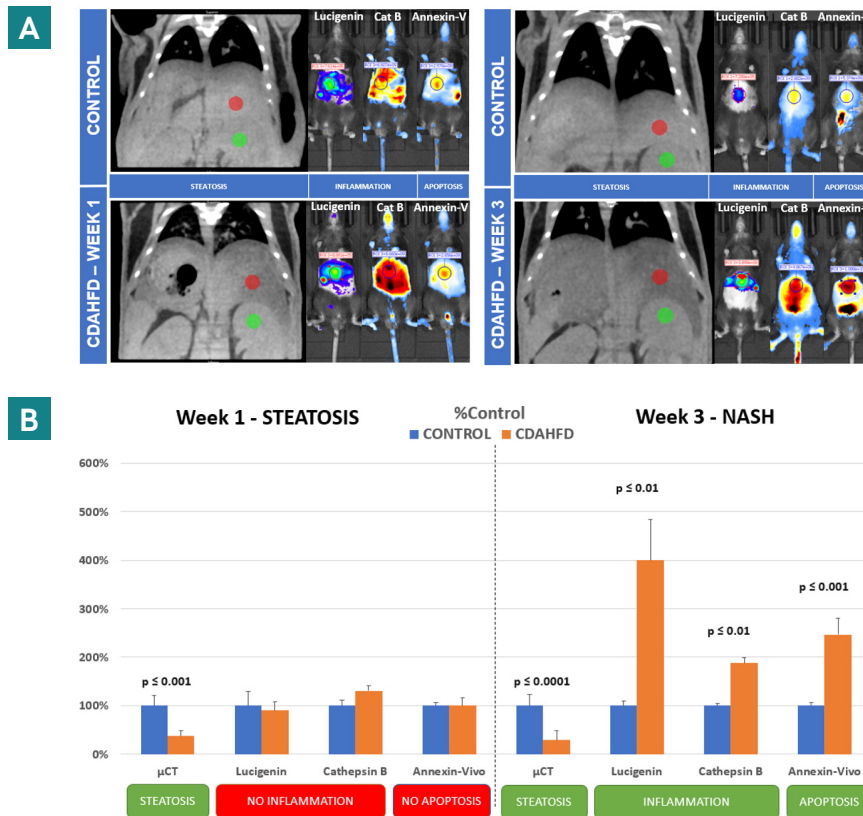


Figure 2: Images were acquired using microCT, chemiluminescence, and fluorescence imaging using the Quantum GX2 microCT and IVIS Lumina series III, respectively (Figure 2A). High-fat diet mice were positive for liver steatosis ($p < 0.001$) on CT imaging but negative for liver inflammation and apoptosis on optical imaging one week after high-fat diet consumption. High-fat diet mice were positive ($p < 0.01$ and $p < 0.0001$) for all NASH imaging markers (CT and Optical) after three weeks on a high-fat diet (Figure 2B)

Conclusion and the future of NASH imaging

This innovative non-invasive *in vivo* imaging approach not only supports the three R's (reduction, replacement, and refinement) but enables longitudinal assessment of disease progression (in the same animal over time) and provides a robust measurement of NASH development (steatosis, inflammation, and apoptosis) in a smaller cohort of animals.

This imaging approach using the IVIS optical platform and Quantum GX2 microCT in combination with Revvity's *in vivo* imaging reagents can be used to investigate the efficacy of liver fibrosis-preventing drugs on NAFLD progression in order to reduce the need for liver transplantation.

Acknowledgements

We would like to thank our collaborators at Galapagos, including Dr. Ludovic Waeckel, Dr. Catherine Jagerschmidt, and Sofia Alves.

References

1. Souveek Mitra et al. Epidemiology of non-alcoholic and alcoholic fatty liver diseases. *Transl Gastroenterol Hepatol* 2020; 5:16.
2. Helmut Denk et al. Animal models of NAFLD from the pathologist's point of view. *BBA - Molecular basis of Disease*. 2019; 929:942
3. Michael Fuchs et al. Lipotoxicity in NASH. *Journal of Hepatology*. 2012; 291:293
4. Gopanandan Parthasarathy et al. Pathogenesis of Nonalcoholic Steatohepatitis: An Overview. *Hepatology Communications*. 2020; 478:492
5. Wenqian Fang et al. Cathepsin B deficiency ameliorates liver lipid deposition, inflammatory cell infiltration, and fibrosis after diet-induced nonalcoholic steatohepatitis. *Translational Research*. 2020; 28:40
6. Tatsuo Kanda et al. Apoptosis and non-alcoholic fatty liver diseases. *World J Gastroenterol*. 2018; 2661:2672
7. Masahiko Matsumoto et al. An improved mouse model that rapidly develops fibrosis in non-alcoholic steatohepatitis. *International Journal of Experimental Pathology*. 2013; 93:103

The Revvity logo is displayed in a lowercase, sans-serif font. It is positioned in the bottom right corner of the page, above a yellow wavy graphic element that spans the width of the footer.