

Assessment of arterial function using MicroCT imaging.

Authors

Alexandre Belenkov, MD, Ph.D.

Olivia J. Kelada, Ph.D.

Revvity, Inc.

Hopkinton, MA

Baktybek Kojonazarov, MD, Ph.D.

Institute for Lung Health (ILH),

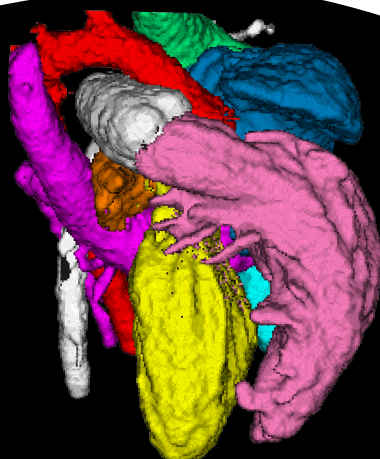
Justus-Liebig University of Giessen, Germany

Introduction

Blood vessel mechanics and function are important aspects of cardiovascular research. Arterial changes have been associated with several pathophysiological conditions, disease states and treatment. These include aging, smoking, obesity, hypertension, atherosclerosis, aneurysm, liver and renal dysfunction, diabetes, and during anti-cancer therapy.

Assessment of the vascular wall mechanical properties of blood vessels is an essential aspect of evaluating arterial function. Structural components of the arterial vessel wall (e.g. elastin, collagen), smooth vasculature tone, and transmural distending pressure are the primary determinants of vascular wall mechanical properties. Alterations in these properties result in end organ damage by imposing hemodynamic stress on vascular beds. Vascular distensibility, for example, defined as the ability of a blood vessel to expand and contract, is a marker of vascular wall mechanical properties. The reduction of arterial distensibility has been reported in patients and animal models with Aortic Aneurysms (AA), Chronic Kidney Disease (CKD), Pulmonary Arterial Hypertension (PAH), Marfan Syndrome (MFS), and in atherosclerotic apolipoprotein E-knockout (apoE- KO) mice.¹⁻⁷

Pulmonary Arterial Hypertension (PAH) is a disease of the small vessels in which there is a substantial increase in pulmonary vascular resistance leading to right ventricle failure and death. Pulmonary arterial distensibility is defined as the change in area across the Pulmonary Artery (PA) between cardiac diastolic and systolic phases. The use of non-invasive imaging of cardiovascular biology and function have traditionally been performed using MRI or ultrasound modalities.



However micro-computed tomography (microCT) provides superior spatial resolution, lower cost and scanning efficiency, as well as ease of use when compared to other conventional modalities. This application note highlights how the Quantum GX microCT system can easily be used to quantify distensibility measurements in a rodent model using contrast-enhanced retrospectively gated computed tomography imaging.

Measuring severe experimental pulmonary arterial hypertension with preclinical MicroCT

Methods

The experiments were performed in concordance with the approved study protocol GI 20/10 33/2013, the University Animal Care Committee and the Regierungspräsidium Giessen and Darmstadt (Hessen, Germany).

To induce Pulmonary Arterial Hypertension (PAH), 7-10-week old Wistar-Kyoto rats (Janvier Labs, Le Genest-Saint-Isle, France) were injected with VEGF receptor inhibitor SU5416 (Tocris Bioscience, Bristol, UK) at 20 mg/kg body weight and subsequently exposed to hypoxic followed by normoxic conditions for a duration of three weeks and two weeks, respectively. SuHX rats were catheterized (a 27-gauge needle and 40 cm long intravenous catheter pre-filled with heparinized saline solution was introduced into a lateral tail vein) and anaesthetized (induction and maintenance with 3% and 1.5% isoflurane in oxygen) respectively, for imaging with contrast.

Retrospectively gated microCT imaging (Quantum GX, Revvity, Inc., Waltham, MA) was performed at 90 kV, 80 μ A for four min (360 degree rotation, 60 frames per second, 14688 projections and GPU-based filtered back projection reconstruction). Imaging was performed in conjunction with the delivery of 5 μ L/g of body weight of eXIA160XL blood-pool contrast agent (Binitio Biomedical, Inc.) infused (Pump11Elite, Instech Laboratories, Plymouth Meeting, PA) at a rate of 0.3 mL/min.

End-systolic and end-diastolic images were analyzed using Analyze 12.0 (AnalyzeDirect, Inc., Overland Park, KS). Oblique Sections were used to align the heart in the long and short axes. Then the pulmonary artery area was delineated in both end-diastolic and end-systolic images using a threshold-based segmentation determined as the full width half max value (FWHM). The main PA distensibility index was calculated in healthy control and SuHX rats as the maximal systolic artery area minus the minimal diastolic artery area, divided by the minimal diastolic arterial area, and multiplied by 100.

$$DI_{PA} = \frac{(A_{MAX} - A_{Min})}{A_{Min}} \times 100\%$$

Equation 1: DI_{PA} is the calculated PA distensibility index, A_{MAX} the maximal artery area (systole), and A_{Min} the minimal artery area (diastole).

Quantification of pulmonary artery distensibility index with preclinical microCT

Results

The PA area was segmented on end-diastolic and end-systolic reconstructions of PAH (n=5) and control (n=5) rats. PAH rats demonstrated a significant decrease of main PA distensibility index compared with healthy controls ($14.04 \pm 2.97\%$ vs $31.53 \pm 8.55\%$, $P < 0.003$). In the clinic, a cut-off value of 16.5% shows the strongest correlation with mean pulmonary artery pressure (mPAP), with a specificity and sensitivity for PAH detection of 96% and 86%, respectively.⁷

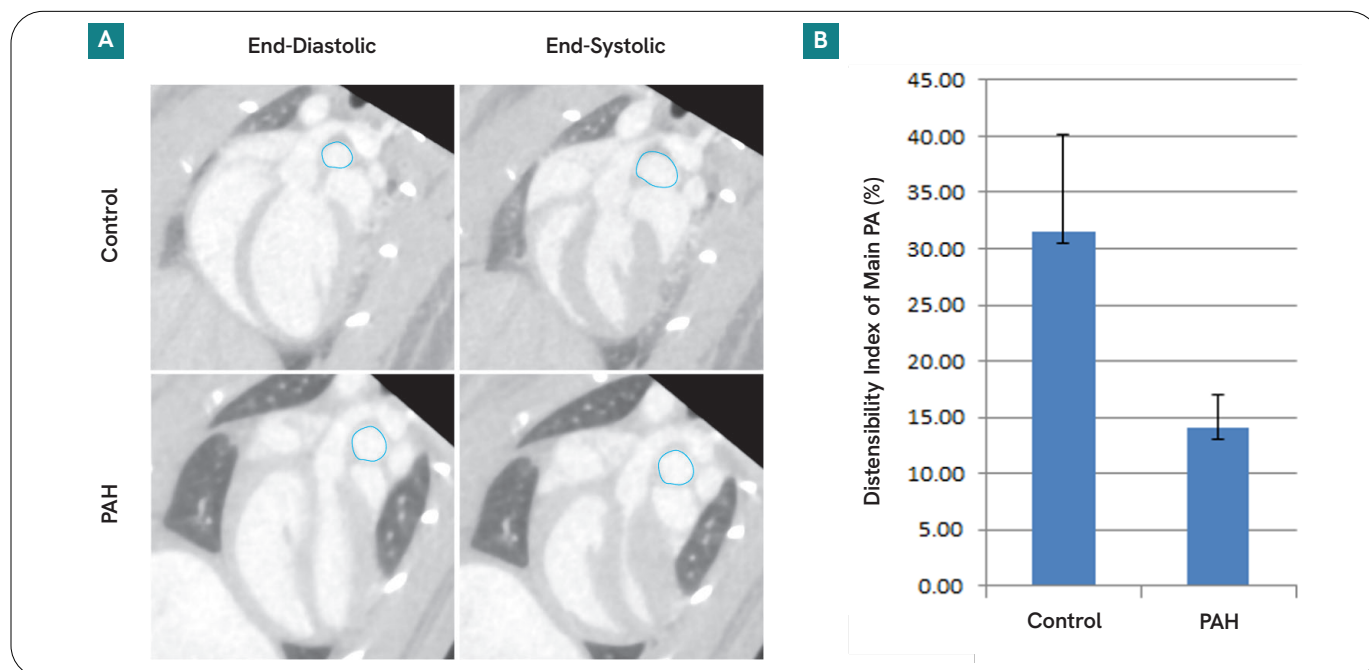


Figure 1. (A) Representative end-diastolic and end-systolic images. PA segmentations (blue) in control (top panel) and PAH (bottom panel) rats. (B) The graph shows the variation in mean main PA percentage between the control and PAH rats (error bars = standard deviation).

Customer testimonial on cardiac imaging using the quantum GX microCT system

Publication author



“The Quantum GX microCT was installed at the University of Giessen in 2015 and has proven to be an excellent tool for preclinical cardiac imaging. Using many methods, such as the one

outlined in this application note, the Quantum GX has allowed us and others to image cardiac function and uncover new aspects of cardiac disease in ways that were not previously possible.”


Dr. Baktybek Kojonazarov, University of Giessen, Germany

Summary

This application note clearly demonstrates that microCT imaging can provide quantitative arterial measurements in a preclinical model. Although, Ultrasound (US) and Magnetic Resonance Imaging (MRI) are the most commonly employed imaging technologies for arterial wall assessment, there are many advantages to microCT. These include (1) faster 3D image acquisition (minutes versus hours) resulting in MRI comparable image quality and resolution (2) more robust and user-friendly acquisition sequences (3) the possibility to acquire 3D and 4D data (4) more geometric accuracy compared to ultrasound (5) much lower cost compared to MRI. These advantages make a strong case for the use of microCT as part of routine preclinical arterial assessment.

References

1. Wang YX et al. Increased aortic stiffness assessed by pulse wave velocity in apolipoprotein E-deficient mice. *Am J Physiol Heart Circ Physiol.* 2000 Feb;278(2):H428-34.
2. Karau KL et al. Microfocal X-ray CT imaging and pulmonary arterial distensibility in excised rat lungs. *Am J Physiol Heart Circ Physiol.* 2001 Sep;281(3):H1447-57.
3. Amirbekian S et al. *In vivo* assessment of blood flow patterns in abdominal aorta of mice with MRI: implications for AAA localization. *Am J Physiol Heart Circ Physiol.* 2009 Oct;297(4):H1290-5.
4. Eberth JF et al. *Ann Biomed Eng.* Mechanics of Carotid Arteries in a Mouse Model of Marfan Syndrome. 2009 Jun;37(6):1093-104.
5. Van der Pluijm et al. *EBioMedicine.* Defective Connective Tissue Remodeling in Smad3 Mice Leads to Accelerated Aneurysmal Growth Through Disturbed Downstream TGF- β Signaling. 2016 Oct;12:280-294.
6. Jardim C et al. Pulmonary artery distensibility in pulmonary arterial hypertension: an MRI pilot study *European Respiratory Journal* 2007; 29: 476-481.
7. Revel M et al. Pulmonary hypertension: ECG-gated 64-section CT angiographic evaluation of new functional parameters as diagnostic criteria. *Radiology* 2009;250 (2):558-566.



revvity